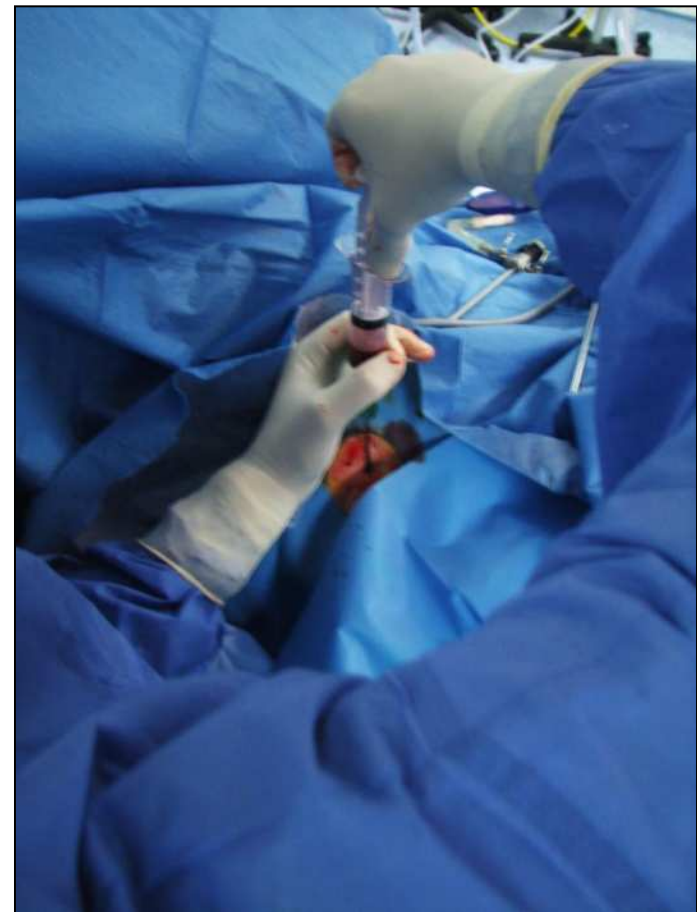
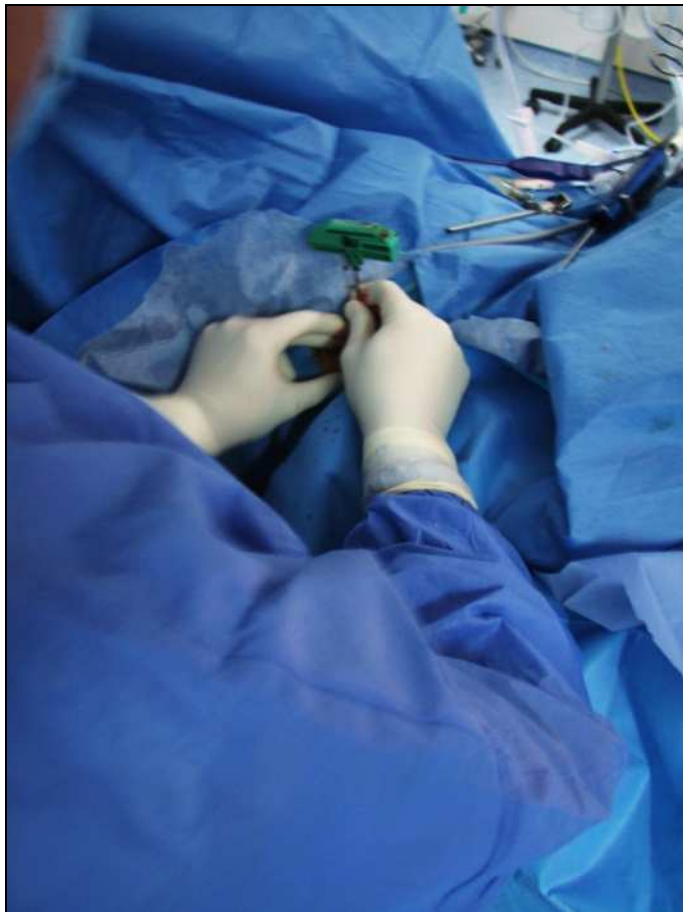
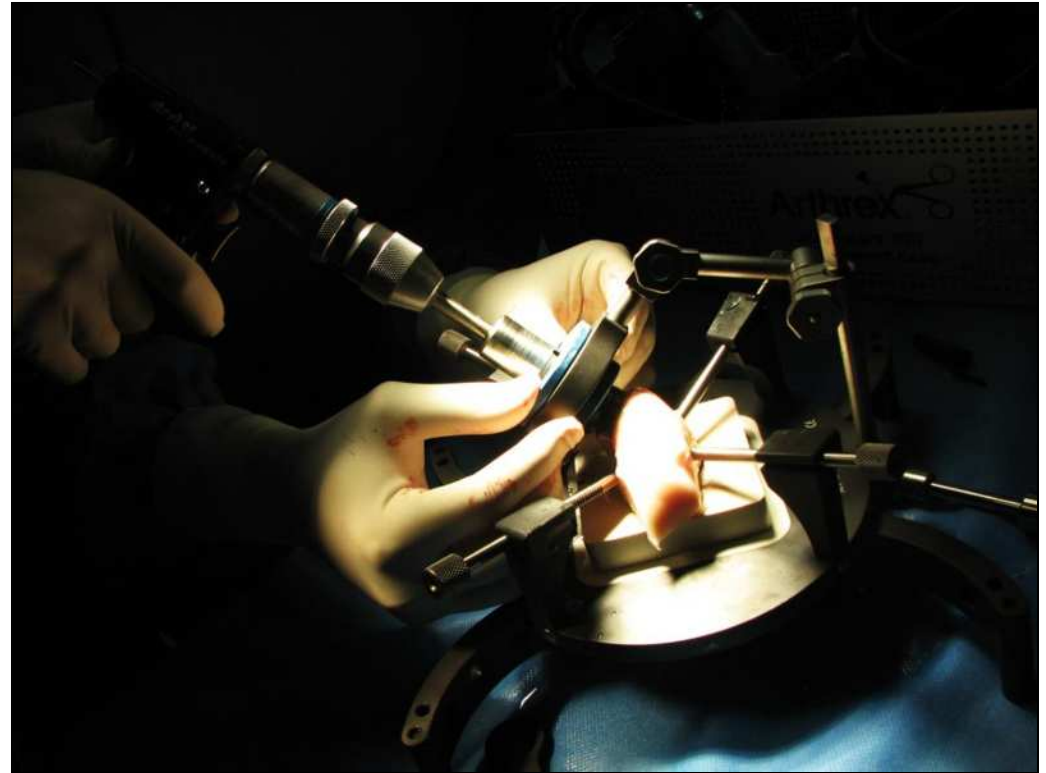
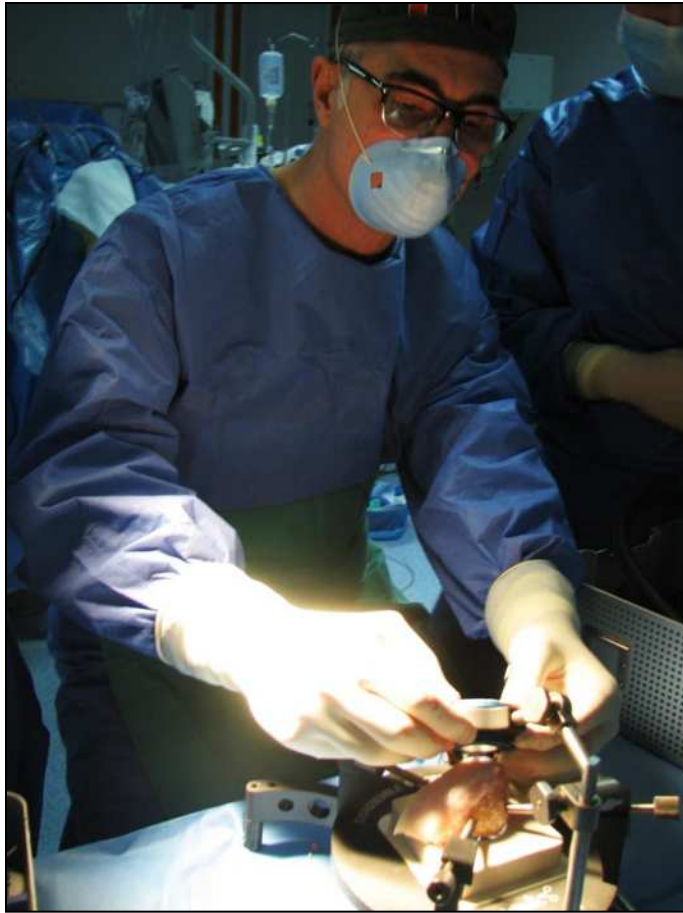

Aloinjertos osteocondrales frescos + MSC

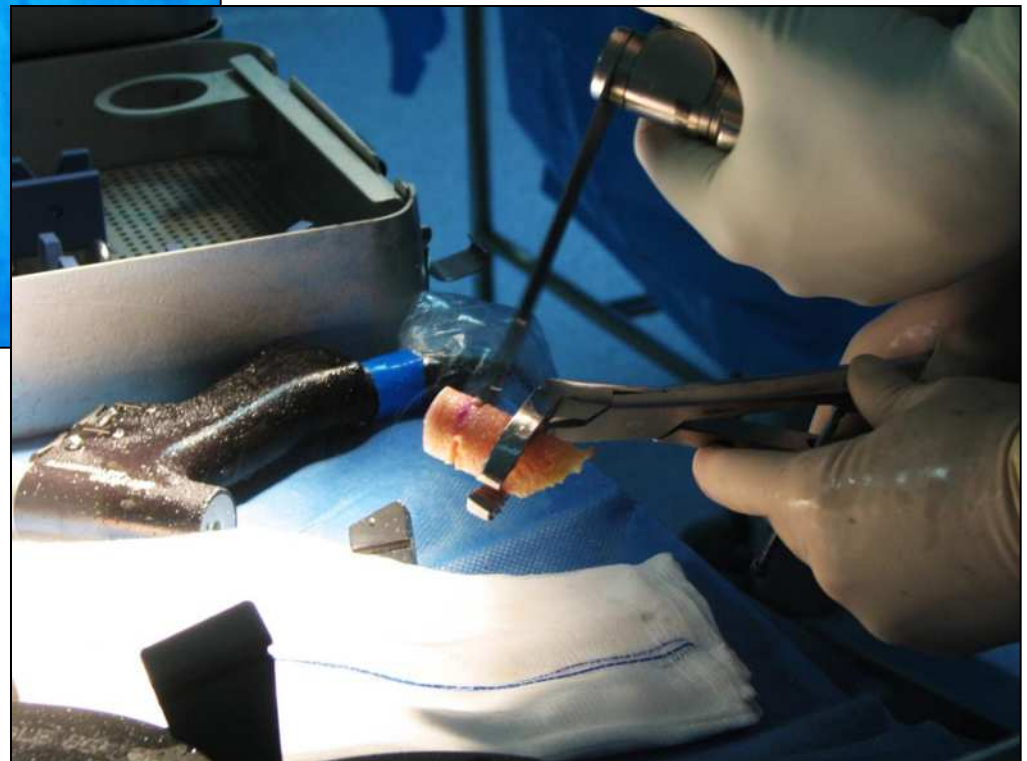


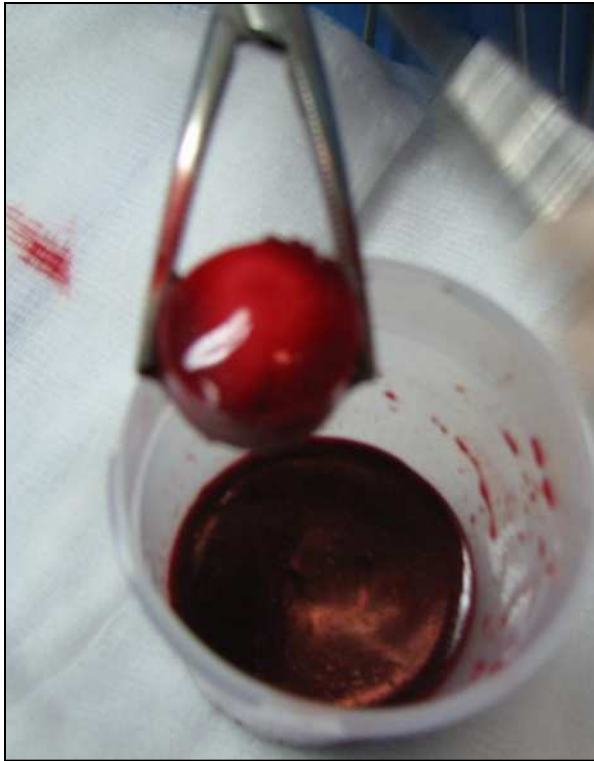

Tallado de la pieza

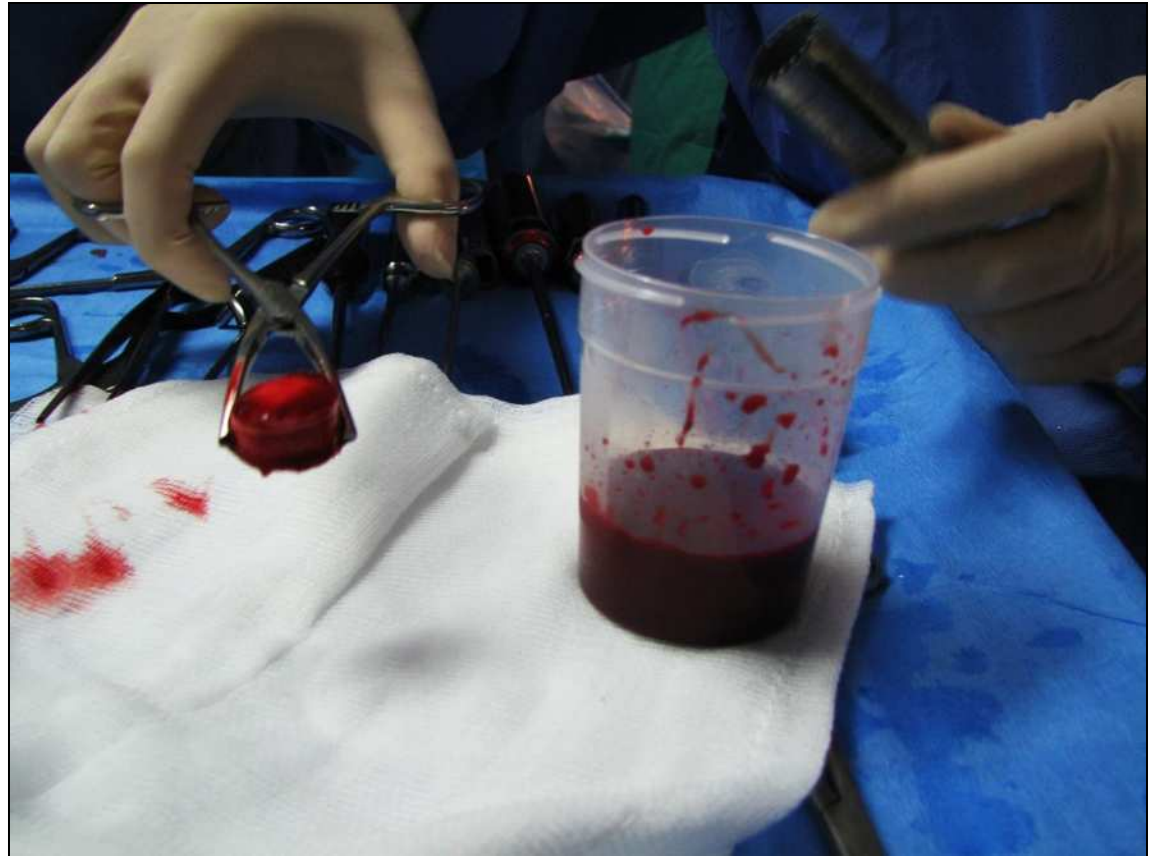

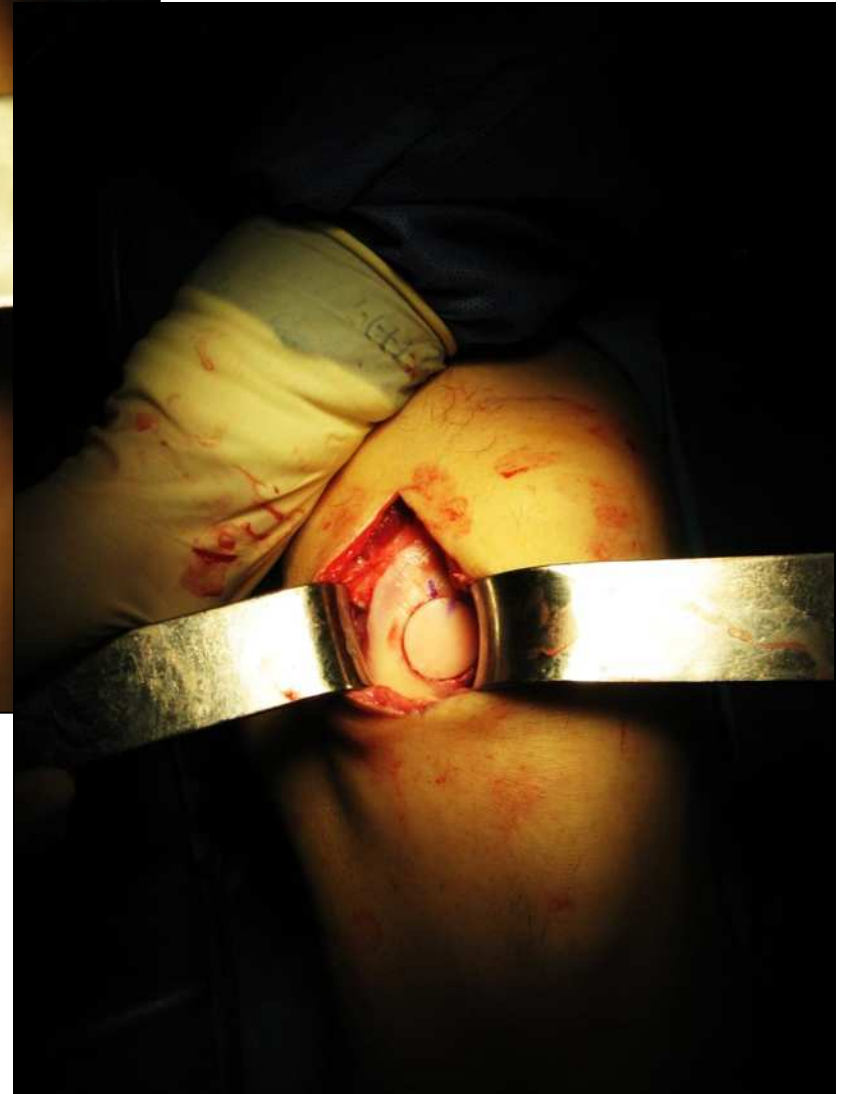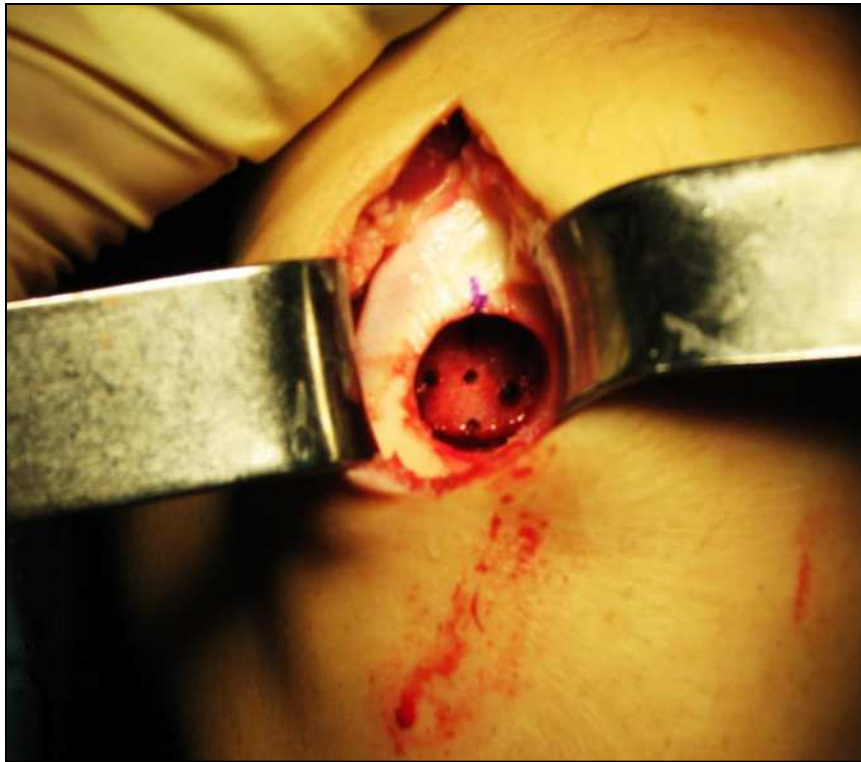Tallado de la pieza





MSC





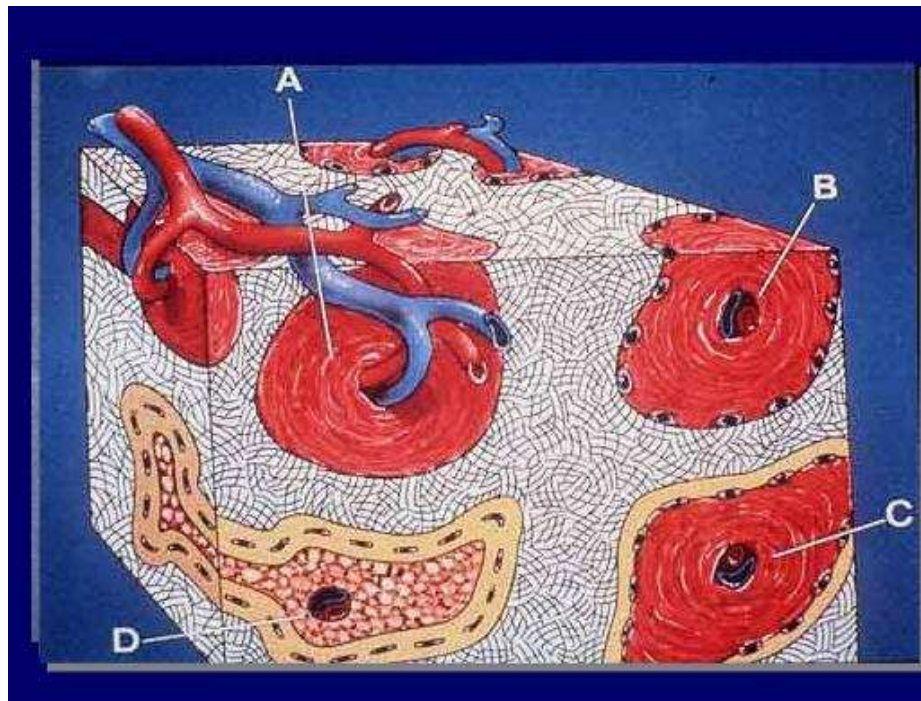
Injerto en marquetería

Aloinjertos osteocondrales frescos

- Donantes jóvenes entre 18 y 25 años con buen estado cartílago articular
- Cumplimiento de la normativa RD1301/2006
- Conservación en medio de cultivo elaborado con el suero del receptor a 37 °C y 5% de CO₂
- Plazo máximo para la implantación 10 días

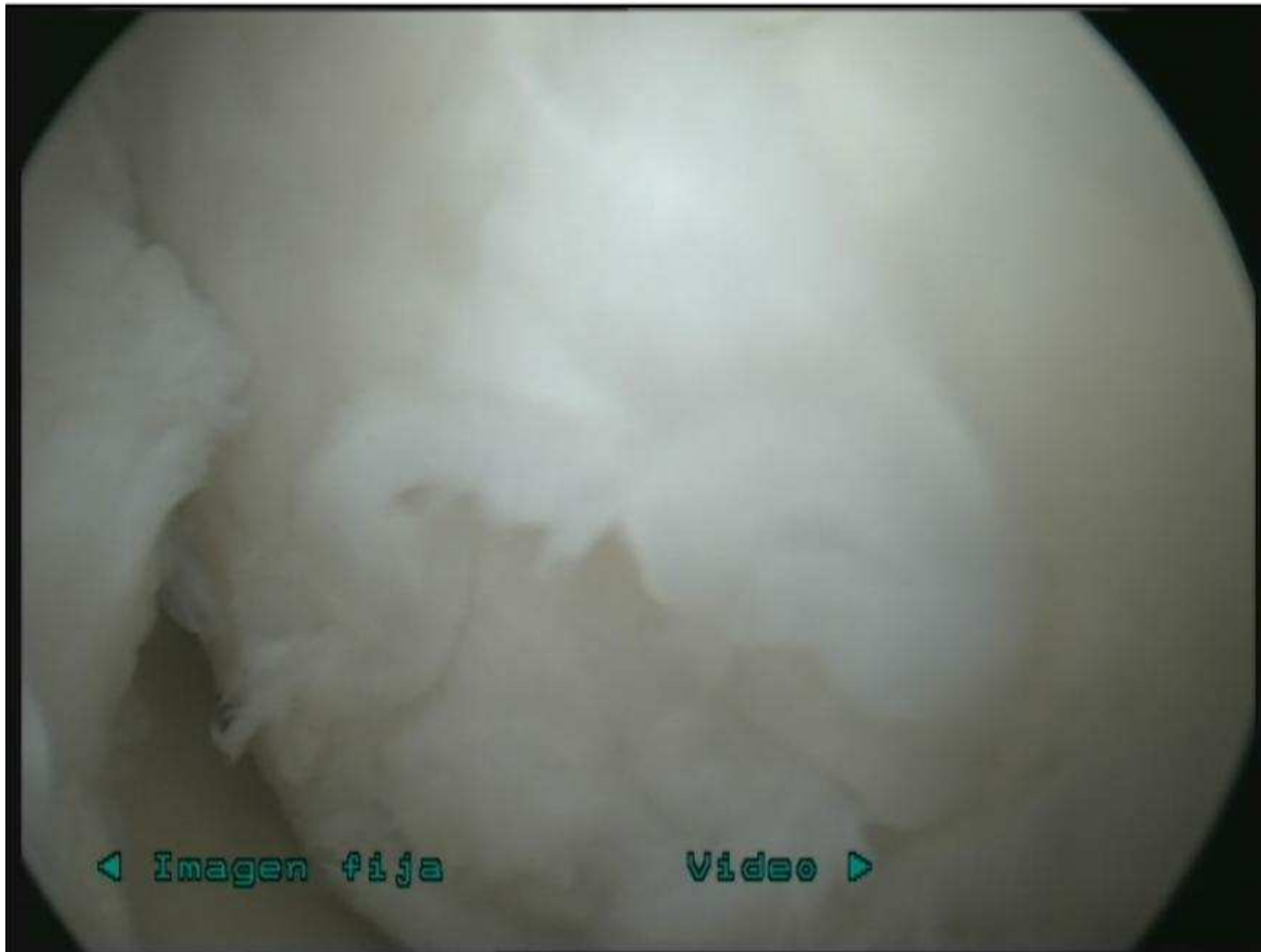MSC

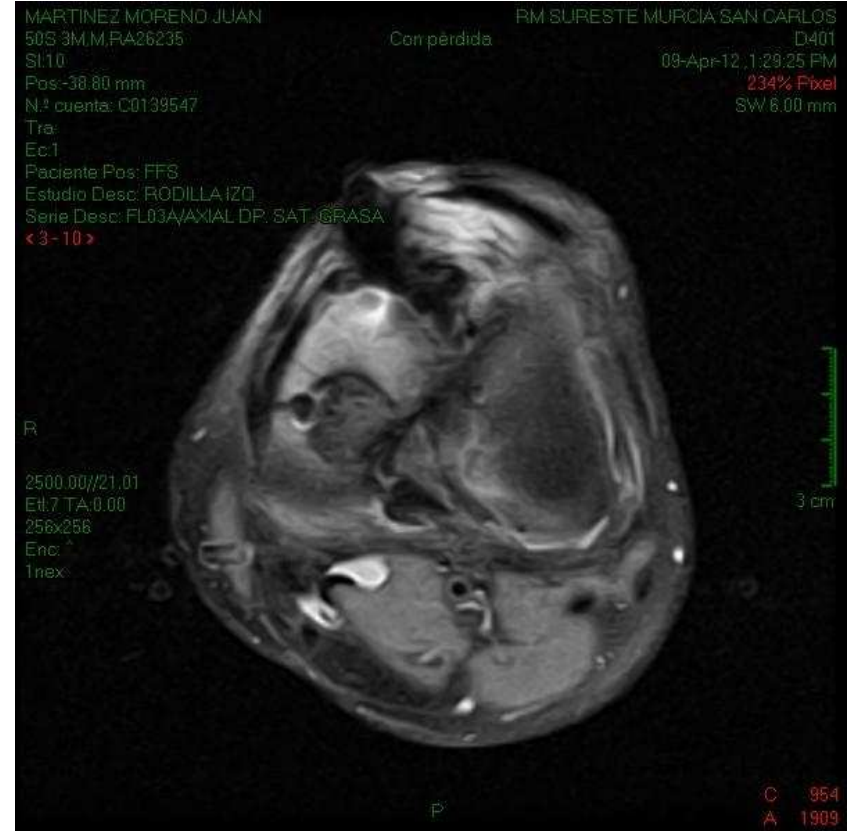
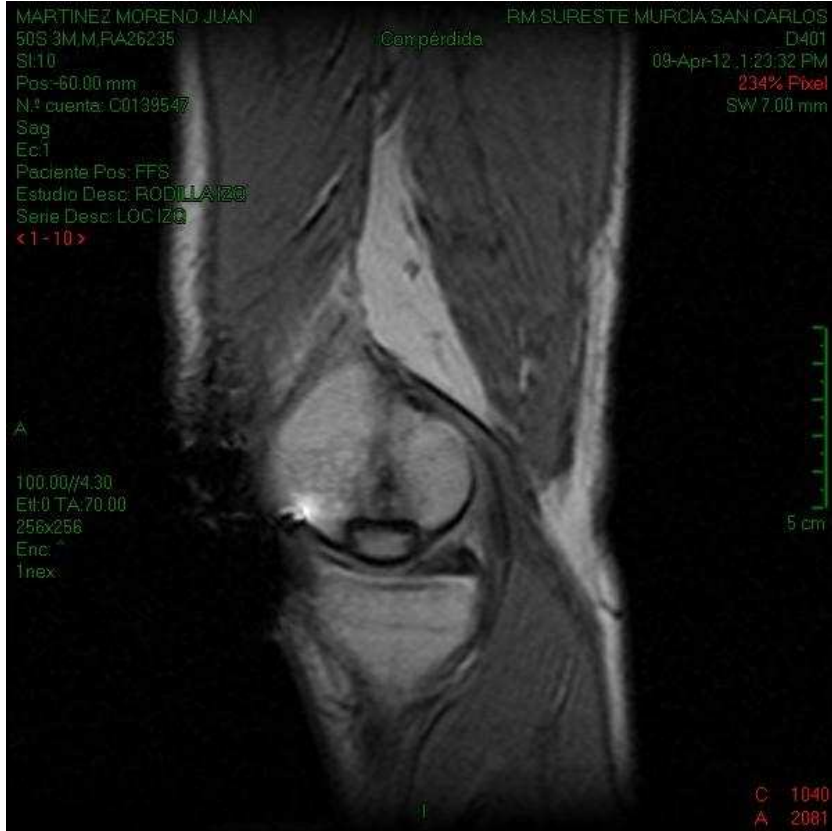Potencial para formar hueso nuevo

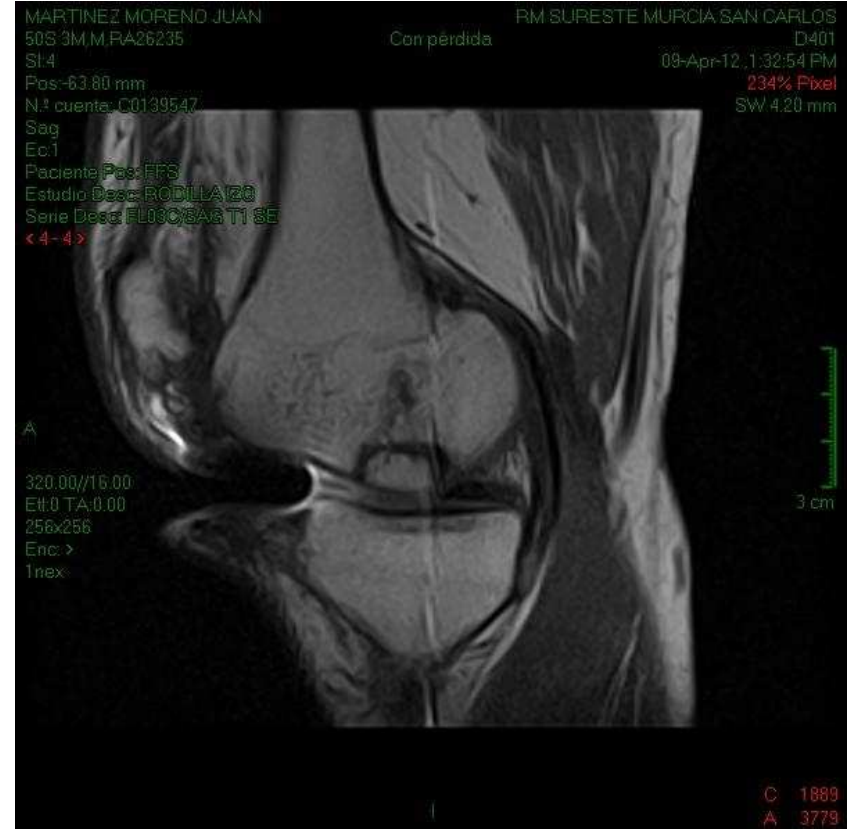
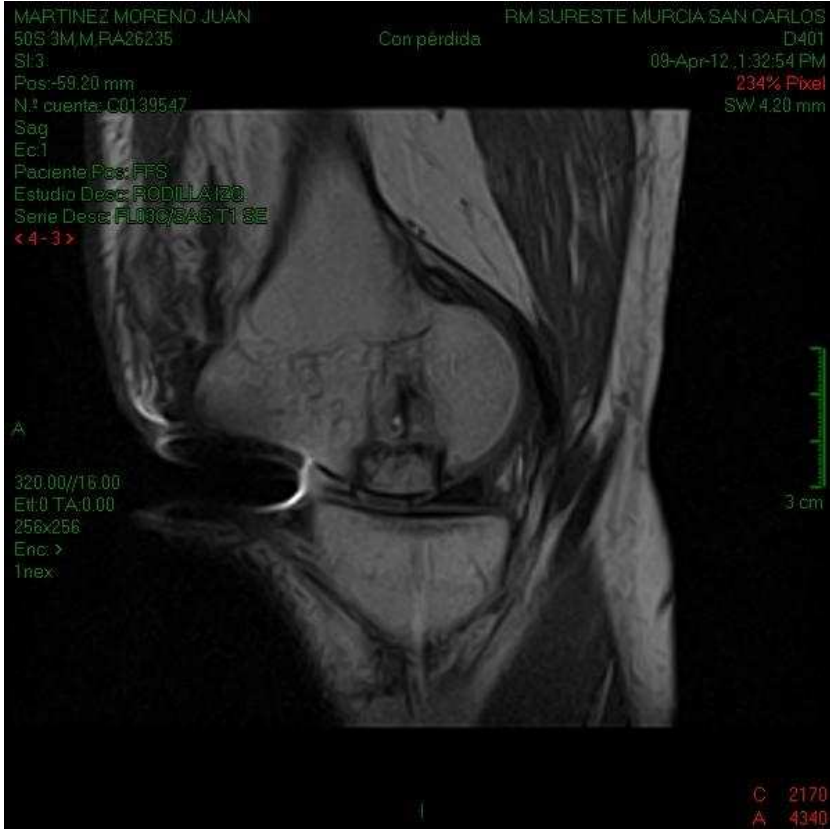
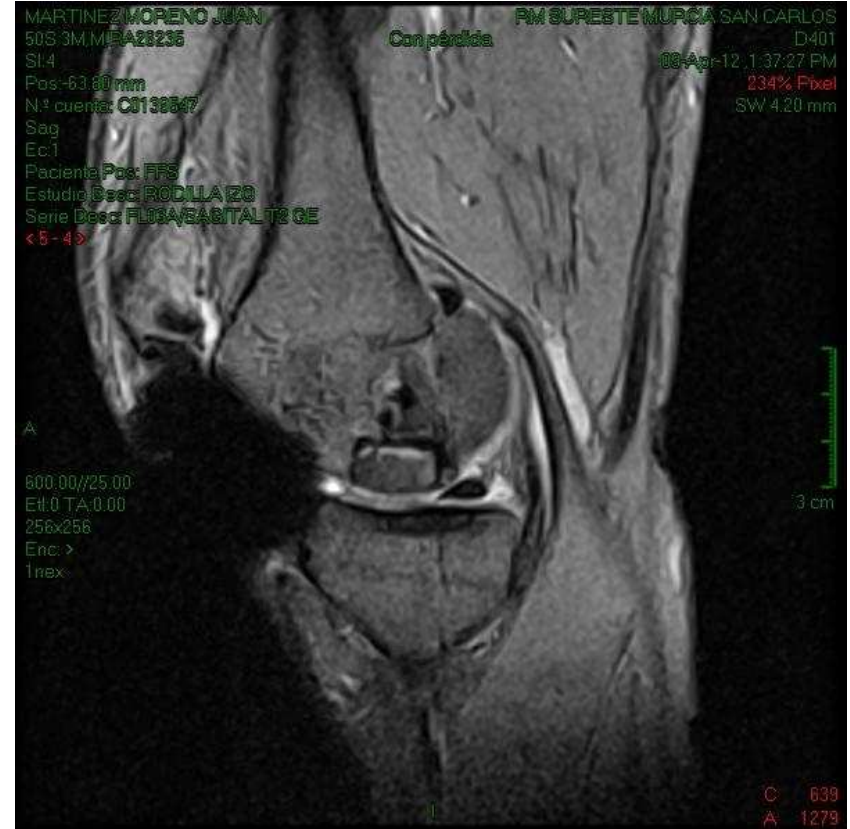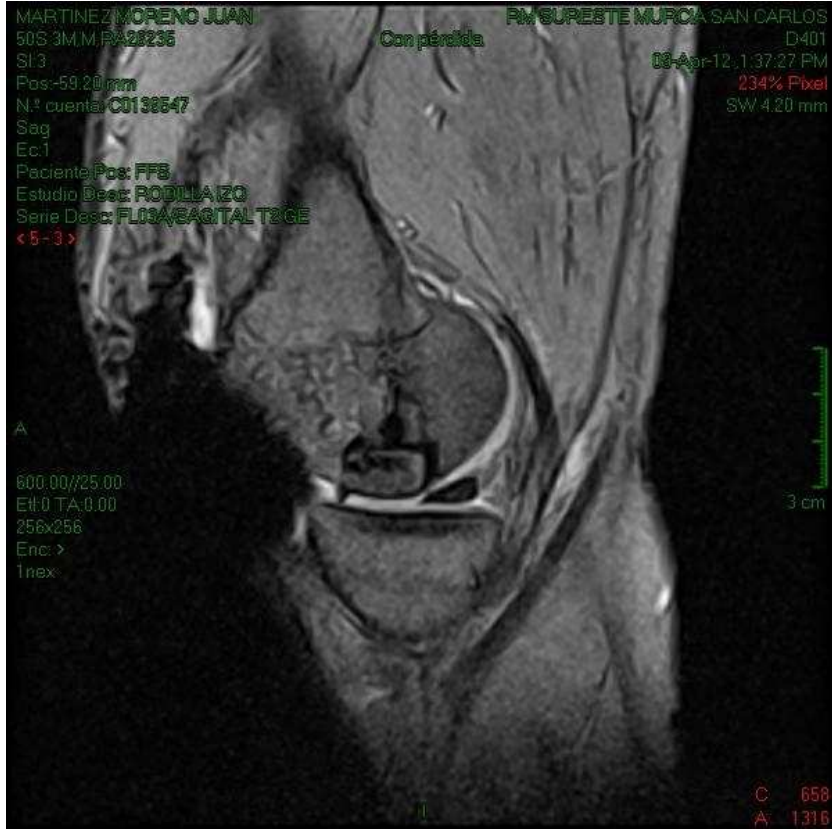 Friedenstein et al, 1966

Caso I

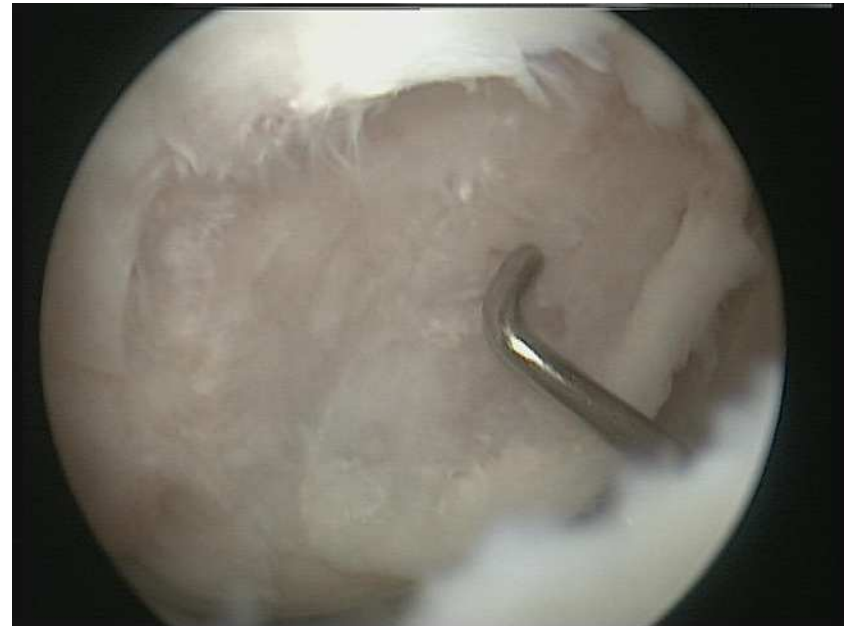
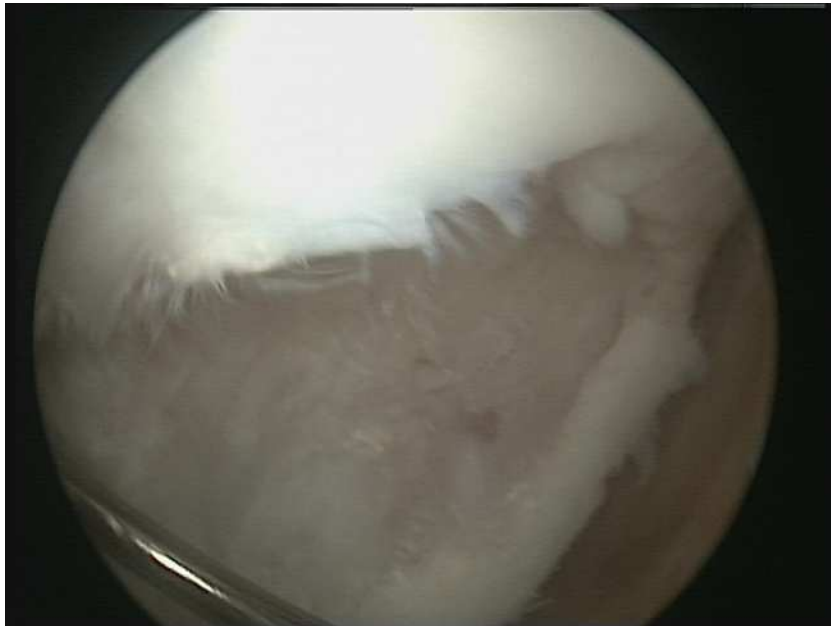

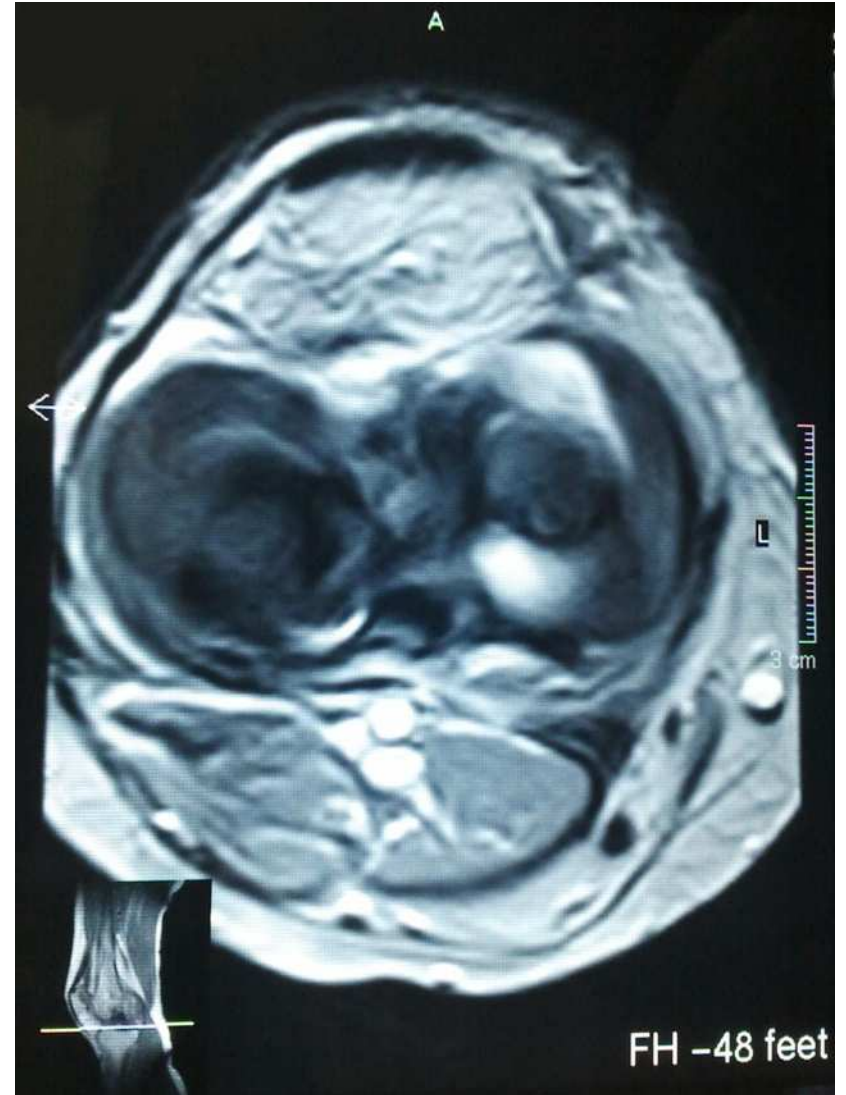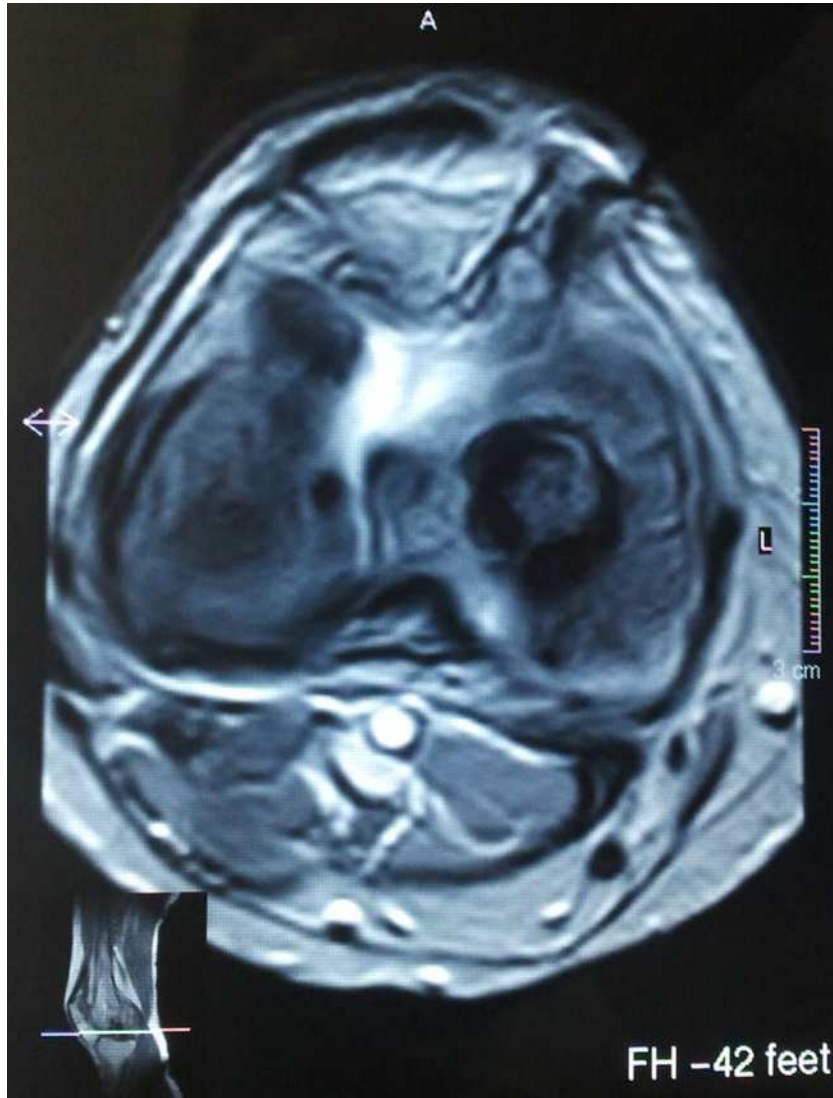


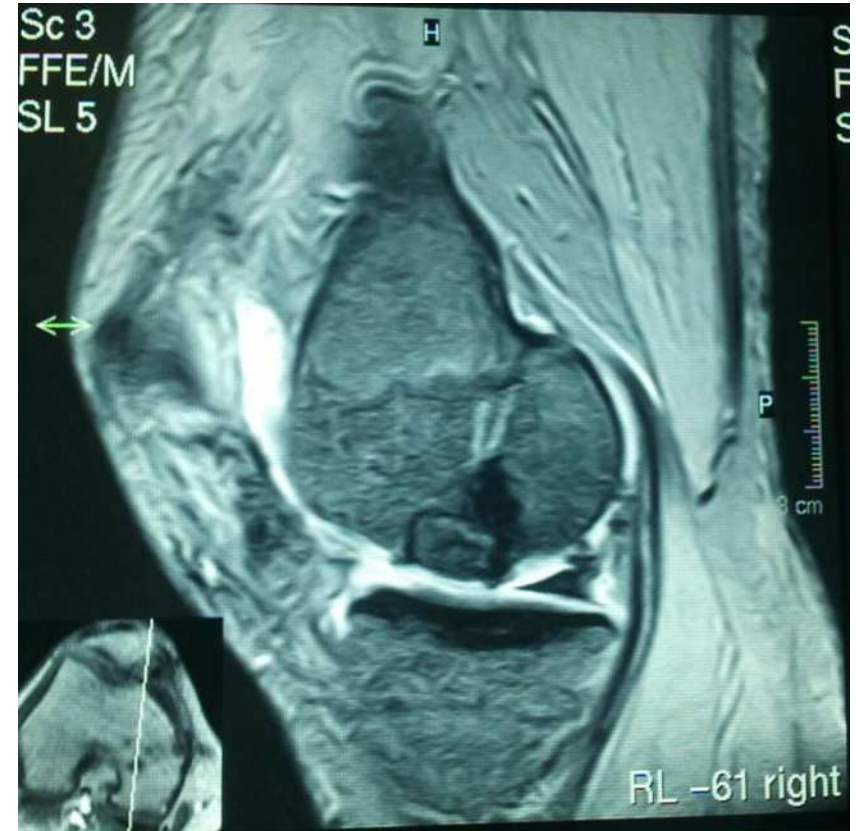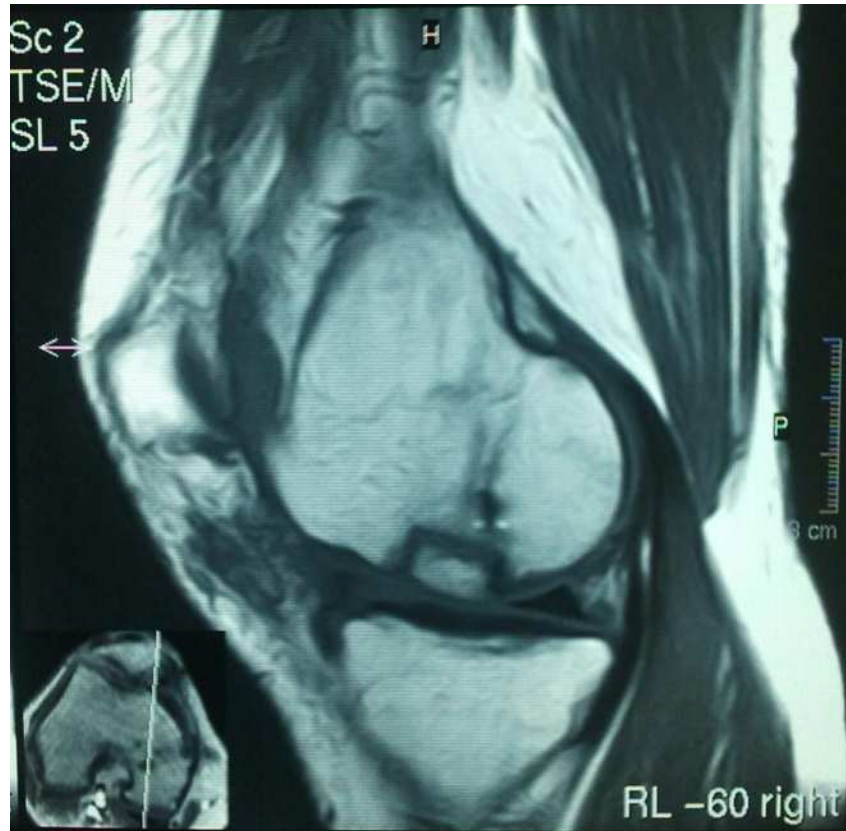




Caso II







Buenos y excelentes resultados en torno al 82%

Aubin PP Cheah HK. Clin Orthop 2001

Chu CR, Convery FR. Clin Orthop 1999

Garret JC. Clin Orthop 1994

Ghazavi MT, Pritker KP. J Bone Joint Surgery 1997

Jamali AA, Emmerson BC. Clin Orthop 2005

*McCulloch PC, Kang RW, Prospective evaluation of prolonged fresh osteonecrosis
allgraft transplantation.... Am J Sport Med, 2007;35:411-20.*