

Arthroscopic Repair of Ankle Instability With All-Soft Knotless Anchors



Hélder Pereira, M.D., Gwen Vuurberg, Nuno Gomes, M.D.,
Joaquim Miguel Oliveira, B.Sc., Ph.D., Pedro L. Ripoll, M.D.,
Rui Luís Reis, C.Eng., M.Sc., Ph.D., D.Sc., João Espregueira-Mendes, M.D., Ph.D., and
C. Niek van Dijk, M.D., Ph.D.

Abstract: In recent years, arthroscopic and arthroscopically assisted techniques have been increasingly used to reconstruct the lateral ligaments of the ankle. Besides permitting the treatment of several comorbidities, arthroscopic techniques are envisioned to lower the amount of surgical aggression and to improve the assessment of anatomic structures. We describe our surgical technique for arthroscopic, two-portal ankle ligament repair using an all-soft knotless anchor, which is made exclusively of suture material. This technique avoids the need for classic knot-tying methods. Thus it diminishes the chance of knot migration caused by pendulum movements. Moreover, it avoids some complications that have been related to the use of metallic anchors and some currently available biomaterials. It also prevents prominent knots, which have been described as a possible cause of secondary complaints.

Ankle sprain is the most frequent injury during sports activity. About 20% of cases eventually require surgical treatment for ankle instability after nonoperative treatment failure.¹ The Broström procedure, with its several modifications, has been considered the gold standard of surgical treatment for several years.^{1,2}

Arthroscopic techniques have recently been described aiming to lower the amount of surgical aggression and shorten the rehabilitation process (Table 1).³⁻¹³ These techniques have been linked to the development of

anchor and fixation devices that have facilitated arthroscopic-assisted ligament repair.¹⁴ From large-diameter (5.5-mm) metal-based anchors⁴ to smaller (2.9-mm) biomaterial-based anchors,^{3,14} several options have been proposed. More recently, all-suture anchors have also been proposed as a reliable fixation method while permitting even smaller drill holes (1.4 or 2.1 mm).¹⁵ This is advantageous when one is perforating a small bone or predicting the eventual need for a revision procedure. Moreover, if an additional implant is required (e.g., failure of anchors placed earlier), using large-diameter and “hard” implants, surgeons would face greater concerns or difficulties than those expected with a smaller and all-soft device.

All-suture anchors might also avoid complications related to metal or so-called biomaterials.^{16,17} These range from foreign-body reactions to cyst formation, migration, or chondrolysis.

Over time, arthroscopy-related knot-tying techniques have been developed for use in shoulder procedures. These require consecutive training and have a somewhat demanding learning curve. Furthermore, such methods inherently have some risk of glove perforation and skin tears, which raises some safety concerns (Fig 1).¹⁸ In addition, movement-induced knot migrations have been described after repeated pendulum movements during knot tying.¹⁹ This phenomenon might cause changes in the direction and security of the knots.

From the Orthopedic Department, Centro Hospitalar Póvoa de Varzim (H.P., N.G.), Vila do Conde, Portugal; 3B's Research Group—Biomaterials, Biodegradables and Biomimetics, University of Minho, Headquarters of the European Institute of Excellence on Tissue Engineering and Regenerative Medicine (H.P., J.M.O., R.L.R., J.E-M.), Guimarães, Portugal; ICVS/3B's—PT Government Associated Laboratory (H.P., J.M.O., R.L.R., J.E-M.), Portugal; Clínica do Dragão, Espregueira-Mendes Sports Center (H.P., J.M.O., R.L.R., J.E-M., C.N.v.D.), and Ripoll y De Prado Sports Clinic (H.P., J.M.O., P.L.R.), FIFA Medical Center of Excellence, Murcia, Spain; and Orthopedic Department, Amsterdam Medical Centre (G.V., C.N.v.D.), Amsterdam, The Netherlands.

The authors report that they have no conflicts of interest in the authorship and publication of this article.

Received May 15, 2015; accepted October 27, 2015.

Address correspondence to Hélder Pereira, M.D., Rua do Visconde n.161, Touguinhó 4480-582, Vila do Conde, Portugal. E-mail: helderduartepereira@gmail.com

© 2016 by the Arthroscopy Association of North America

2212-6287/15455/\$36.00

<http://dx.doi.org/10.1016/j.eats.2015.10.010>

Table 1. Systematic Review of Clinical Publications (Including Technical Notes) on Topic of Ankle Instability Arthroscopic Repair

	Type of Study	Notes
Takao et al., ⁵ 2015	Technical note	Repair of the lateral ligament alone using a lasso-loop stitch, which intends to avoid additional tightening of the inferior extensor retinaculum
Lui, ⁶ 2015	Technical note	Modified Broström-Gould procedure; bone tunnels and transosseous sutures
Guillo et al., ⁷ 2014	Technical note	Hamstring autograft required
Guillo et al., ⁸ 2014	Technical note	Hamstring autograft required
Matsui et al., ⁹ 2014	Technical note	Modified Broström-Gould procedure
Vega et al., ³ 2013	Case series (n = 16)	Modified Broström-Gould procedure; 2.9-mm knotless anchor made of PEEK
Cottom and Rigby, ¹⁰ 2013	Case series (n = 40)	Modified Broström-Gould procedure; bioabsorbable bone anchor (no further details available)
Acevedo and Mangone, ¹¹ 2011	Case series (n = 23)	Modified Broström-Gould procedure; bioabsorbable bone anchor, PLDLA based
Kim et al., ¹² 2011	Case series (n = 28)	Modified Broström-Gould procedure; bioabsorbable bone anchor, PLDLA based (no further details available)
Nery et al., ¹³ 2011	Case series (n = 40)	Modified Broström-Gould procedure; 5.0-mm titanium bone anchor; mean follow-up, 9.8 yr
Corte-Real and Moreira, ⁴ 2009	Case series (n = 31)	Modified Broström-Gould procedure; 5.0-mm titanium bone anchor

NOTE. An electronic search was performed using the keywords “arthroscopic,” “ankle ligaments,” “repair,” “surgery,” and “reconstruction” in PubMed and ScienceDirect from 2009 to July 2015. The reference lists of identified publications and journals’ electronic databases were also checked for the same period. This period was chosen based on when the first clinical experience on arthroscopic-assisted lateral ankle ligament repair took place, in 2009.⁴

PEEK, polyether ether ketone; PLDLA, poly-L/D-lactide.

For these reasons, we have decided to adjust our arthroscopic technique for lateral ankle ligament repair by adapting an implant recently developed primarily for shoulder surgery. This is an all-soft knotless anchor composed entirely of suture material: JuggerKnotless (Zimmer Biomet, Warsaw, IN). This technical note describes the surgical procedure step by step.

Surgical Technique

The patient is in the supine position with a pneumatic tourniquet around the thigh. A sandbag is placed under the ipsilateral buttock to rotate the hip internally (foot perpendicular to the ground) (Fig 2).

Distraction should not be applied during this procedure.²⁰ Distraction hinders inspection of the anterior

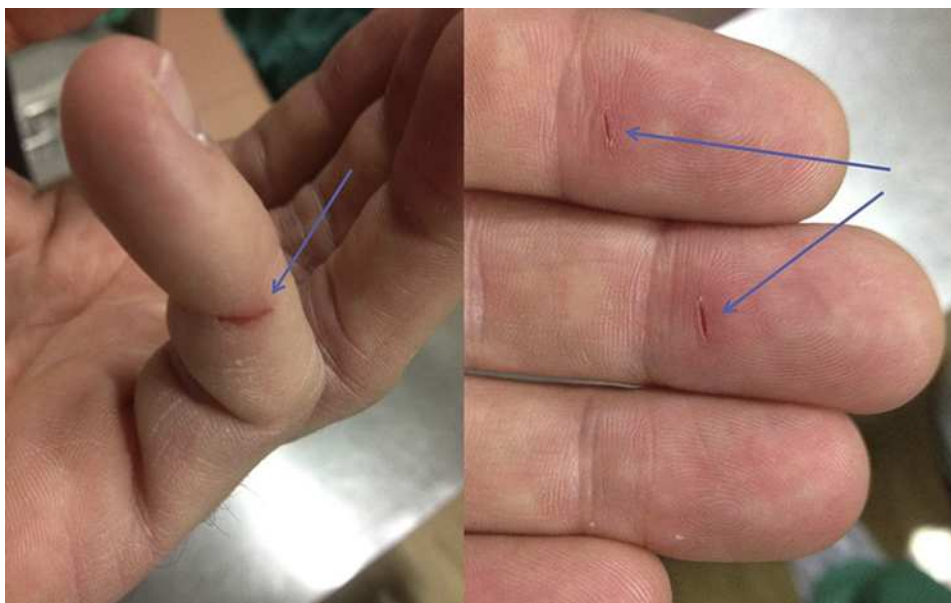


Fig 1. Skin tears caused by knot tying (arrows) after arthroscopic surgery.

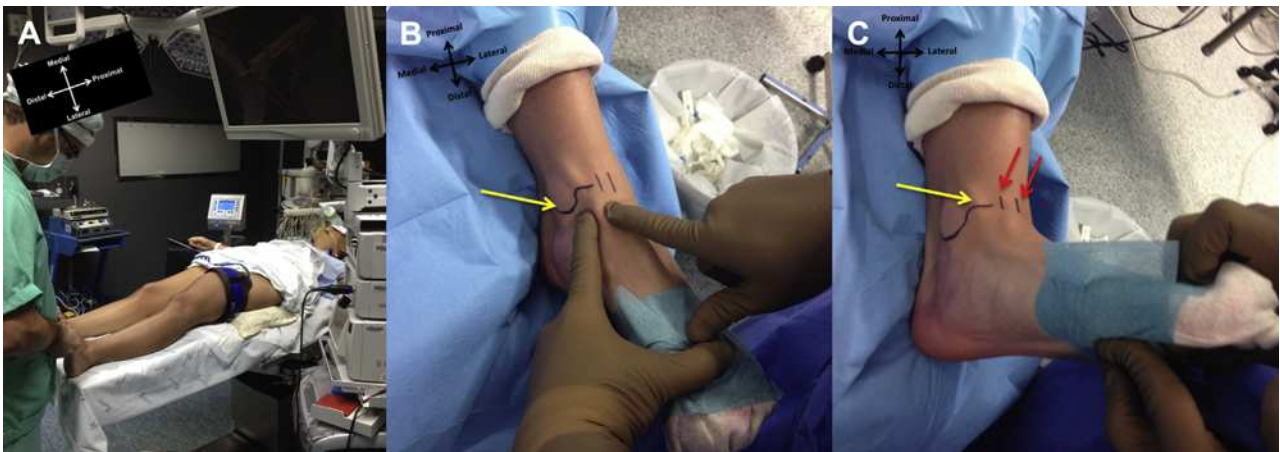

Fig 2. Patient positioning showing left ankle surgery, with a sandbag under the ipsilateral buttock for internal rotation of the limb (A). Correct placement of the medial portal is a key to success. (B, C) The contour of the medial malleolus is drawn on the skin up to the joint line (yellow arrows). (B) In plantar flexion, the tibialis anterior tendon has a more medial position (entrapped between surgeon's fingers), whereas (C) in dorsiflexion, it slides to the center of the joint (between the red arrows).

talofibular ligament (ATFL) and fibula. It also diminishes the anterolateral working space.² Lastly, distraction counteracts shortening of the ligaments.

The most important landmarks are the lateral malleolus (LM), medial malleolus, anterior joint line, and tibialis anterior tendon (TAT) (Figs 2 and 3). As shown in Video 1, the TAT is easily palpable. Its position is significantly more medial in plantar flexion compared with dorsiflexion (Figs 2 and 3). For this reason, a standard medial portal is made with the ankle in dorsiflexion, just medial to the TAT (as close as possible to the center of the joint).

A 4.0-mm arthroscope is introduced through the medial portal, and serum inflow is provided by simple gravity. The joint is inspected and the ATFL identified (Fig 4), while the ankle is kept in dorsiflexion.²¹

An accessory lateral portal (aLP) is created around 1.0 to 1.5 cm anterior to the tip of the fibula. It is recommended to achieve this with transillumination to protect the superficial peroneal nerve. A 22-gauge needle is used to assist in portal placement. In cases without comorbidities, this accessory portal can be used as a unique working portal (two-portal technique). If other concomitant procedures are required, we proceed as described elsewhere.²⁰

The full course of the ATFL must be visible and accessible. The remnants of the ATFL are inspected, and a probe is used for palpation, tensioning, and judging the quality of the tissue (Fig 5). If the remnant is considered acceptable for the modified Broström-Gould procedure, the surgical procedure is completed as planned. If not, the procedure is interrupted and an

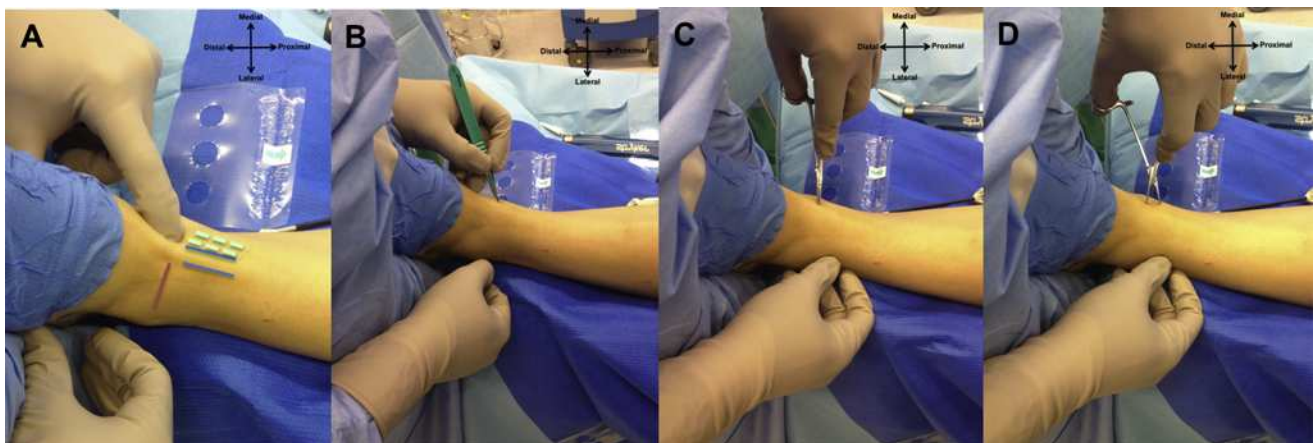


Fig 3. Creation of medial portal in a left ankle. (A) In dorsiflexion, at the level of the joint line (red line), a soft spot can be felt just medial to the tibialis anterior tendon (blue lines). Notice that in plantar flexion position the tendon is considerably more medial (dashed lines). The medial portal is created medial to the intersection of the tibialis anterior tendon and the joint line. (B) A surgical blade is used to cut the skin. (C, D) A mosquito clamp is used to bluntly dissect the soft tissue until reaching inside the joint. The ankle is kept in dorsiflexion at all times to open the anterior "working area," diminish tension of the surrounding structures, and protect the joint cartilage.

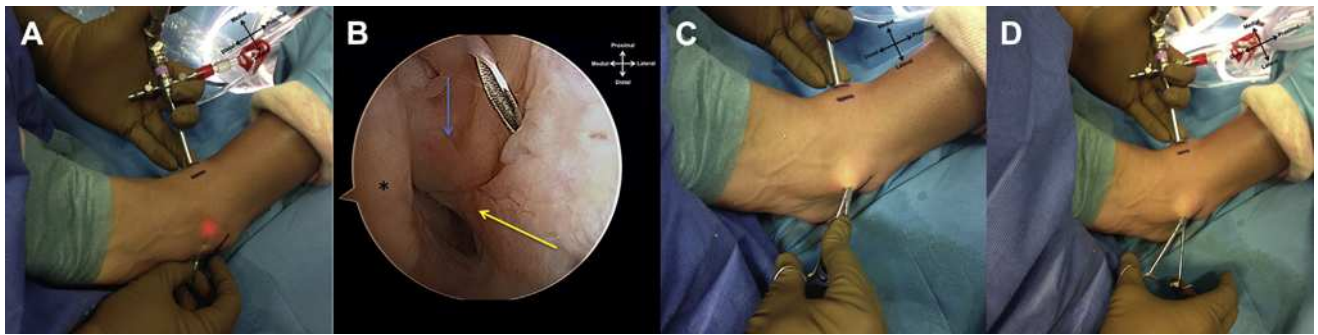


Fig 4. (A) As shown in a left ankle, a 22-gauge needle is used to assist in portal placement 1.0 to 1.5 cm anterior to the tip of the fibula while transillumination is used to protect the superficial peroneal nerve. (B) The tip of the lateral malleolus (blue arrow) and the remnant of the anterior talofibular ligament (yellow arrow) are identified. The talus is also visible (asterisk). (C, D) The surgical blade is used to cut the skin, and blunt dissection by a mosquito clamp is used to penetrate the joint, lowering the risk of iatrogenic injuries.

alternative technique (which had previously been discussed with the patient) is performed.^{1,8}

The surrounding tissue or synovitis can be removed, and the tip of the LM is prepared for anchor placement with a shaver or electrocoagulation device until bleeding bone is achieved. Both anchors are sequentially introduced through the aLP (Fig 5).

The surgeon places the first JuggerKnotless device more distally, aiming for the footprint of the ATFL. A blunt trocar is used inside a drill guide. The direction of the guide is placed with respect to the bone morphology of the LM and is usually directed anterior to posterior at approximately 45° to 60° of the longitudinal axis of the

fibula and parallel to the plane of the lateral gutter. A 2.1-mm drill bit is used, creating a 17-mm-long tunnel (control is provided by a laser mark and safety stop). After tunnel creation, while the guide is maintained in the same position and direction, the anchor is introduced. The surgeon follows the course of the anchor using direct arthroscopic visualization. The anchor is fully introduced by gently tapping with a hammer until it reaches the safety stop. Once fully introduced, the guide is removed and both ends are pulled at the same time to ensure adequate fixation to bone. After this important step, the surgeon must ensure that both ends of the anchor are adequately sliding. With this device, a

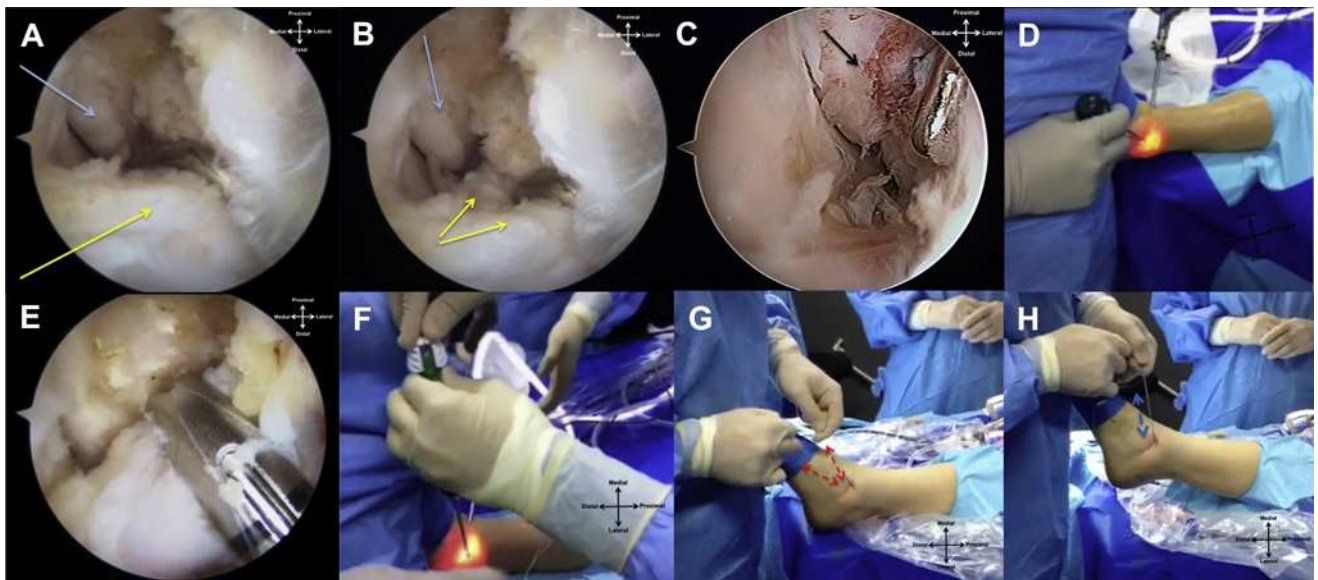


Fig 5. (A, B) Arthroscopic view of the lateral gutter of a left ankle through the anteromedial portal. The quality of the anterior talofibular ligament remnant (yellow arrows) must be inspected, and the contour of the tip of the medial malleolus (blue arrows) is identified. (C) A key to success is for the surgeon to prepare the tip of the lateral malleolus using a shaver blade until reaching bleeding bone before inserting the anchor (black arrow). (D) JuggerKnotless anchor (Zimmer Biomet) placement through the lateral portal. (E) Inside view of the anchor guide (the arthroscope is in the medial portal). (F) Introduction of the anchor. (G) Verification that both ends of the anchor are adequately sliding. (H) Confirmation of the pullout resistance of the anchor by raising the leg from the table while pulling through the anchor wires.

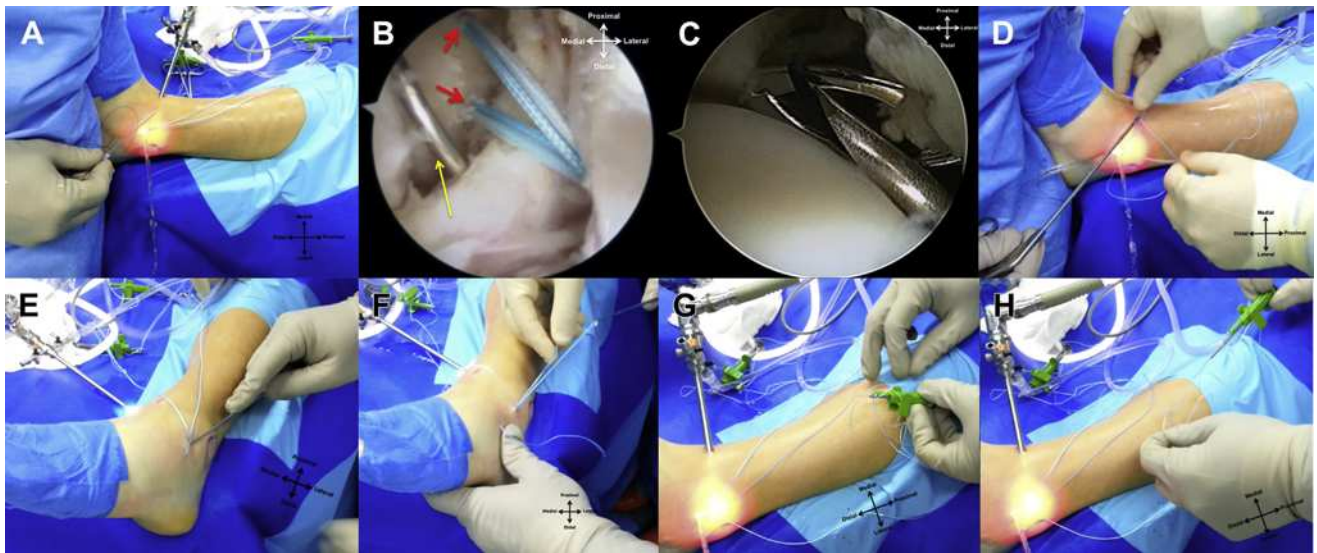


Fig 6. (A) An 18-gauge needle with a No. 3-0 nylon loop is introduced through the accessory lateral portal and serves as a suture passer. (B) Two anchors have been inserted in the lateral malleolus (red arrows). The needle (yellow arrow) trespasses the proximal half of the anterior talofibular ligament remnants. (C) A grasper is used to retrieve the nylon loop. (D) By use of the grasper, the nylon loop is retrieved outside the joint and the solid-blue wire from the first anchor is passed through. The nylon loop (including the solid-blue wire) is then pulled out through the skin. (E, F) Retrieval of the solid-blue wire through the accessory lateral portal with a hook probe. (G) The solid-blue wire of the anchor is passed through the nitinol loop of the deployment device. (H) A second, blue-white loop is detached and slides over the solid-blue wire. Soft tissue is tensioned against the footprint by pulling the solid-blue wire. A small pull on the blue-white wire locks the mechanism.

Fig 7. Left ankle with the arthroscope through the medial portal. (A) The anterior talofibular ligament remnant (yellow arrows) is reattached to the footprint (black arrow) by the first anchor. (B) Final tensioning of the anterior talofibular ligament remnant is achieved in one single continuous movement. (C) The free space in the lateral gutter has diminished. There are no bulky knots around the anchor attachment (black arrow), and the two ends of the second anchor are visible (orange arrows). These are used to perform a pants-over-vest reinforcement with the inferior extensor retinaculum. (D) The second anchor (orange arrow) is also pulled in a continuous movement to tension the tissue of the inferior extensor retinaculum toward the lateral malleolus (red chevrons).

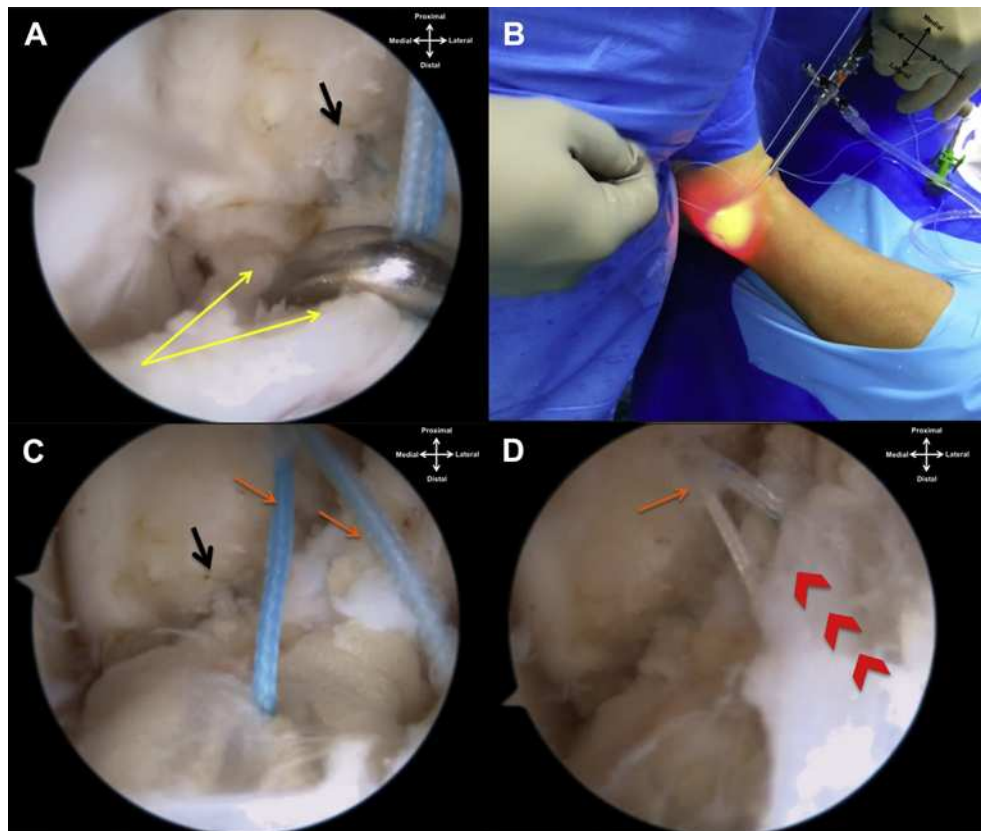


Table 2. Pearls and Pitfalls of Procedure

Pearls	Explanation
No distraction system is required. Ankle dorsiflexion during the procedure is a key to success.	The dorsiflexion method for anterior ankle arthroscopy creates an anterior working space and relaxes the anatomic structure during the procedure, thus lowering the rate of complications.
The surgeon should create the medial portal as close as possible to the center of the joint—just medial to the TAT—in full dorsiflexion at the level of the joint line.	This facilitates access to the lateral gutter. Most work is performed with the arthroscope in the medial portal, and the working instruments are inserted through the accessory lateral portal.
The surgeon should use the surgical blade only to cut the skin.	This prevents iatrogenic injuries.
The surgeon should use blunt dissection (our suggestion is to use a mosquito clamp) to create the portals and to prepare the subcutaneous tissue.	This prevents iatrogenic injuries.
The accessory lateral portal should be created under direct control with the arthroscope in the medial portal.	A needle is used to confirm that the portal will permit adequate instrument orientation before incision. Transillumination helps to reduce iatrogenic damage to the superficial nerves and vessels.
Inspection and dissection of the remnant of the ATFL comprise a key to success.	This is decisive for the outcome of the procedure. At this point, a final decision is made either to proceed as planned or to perform another repair or reconstruction technique.
The surgeon should debride the tip of the lateral malleolus until reaching bleeding bone before putting the anchors in place.	This step will enhance the biological reaction, thus facilitating the healing of the ligament.
The surgeon should take care to keep the anchor guide in place and in the same direction while drilling the bone tunnel and until the anchor is finally tapped in place.	If the direction of the guide changes during the procedure, it might result in failure of anchor deployment.
Immediately after putting the anchor in place, the surgeon should confirm	If there is some problem impairing proper functioning of the

Table 2. Continued

Pearls	Explanation
pullout resistance and also that both ends of the anchor are adequately sliding.	anchor, this is the most adequate time to solve it.
The surgeon should make sure to keep both ends of each anchor always connected.	This prevents confusion and mistakes during the procedure, which could cause messing of the wires between both anchors and result in secondary errors.
The surgeon should avoid over-tensioning of the structures and always confirm that passive full dorsiflexion and plantar flexion are possible after ligament repair.	Excessive tension might cause secondary complaints after Broström-Gould repair.
Pitfalls	
The use of a needle as a suture passer can be considered a pitfall.	It might cause iatrogenic damage within the joint and to the ATFL remnant. More adequate instruments might be developed in the future.
The surgeon should avoid making multiple perforations when passing through the ATFL remnant with the 18-gauge needle.	This might cause iatrogenic damage to the remnant of the ligament.

ATFL, anterior talofibular ligament; TAT, tibialis anterior tendon.

Table 3. Advantages and Limitations of Procedure

Advantages
Arthroscopy enables better tissue characterization.
Arthroscopy provides less postoperative swelling and discomfort.
Arthroscopic ligament repair provides better esthetic results.
There is a small amount of aggression to bone (2.1-mm drill tunnel).
There is a small risk of complications inherent to rigid anchors once these implants are made of all-soft, all-suture material.
The technique does not require experience in knot-tying techniques.
The technique diminishes the risk of bulky knots and knot migration.
The technique diminishes the risk of glove perforation and skin tears.
Limitations
Ankle ligament arthroscopic repair requires previous experience in ankle arthroscopy.
Few specific instruments have been developed for this specific purpose. This fact might create additional difficulties.
This procedure is not “universal.” It is only indicated when the remnant of the ATFL is considered suitable for repair.
Objective preoperative and perioperative criteria to define which ATFL remnants are suitable for repair are lacking.
The use of suture anchors increases the cost compared with some classic techniques.

ATFL, anterior talofibular ligament.

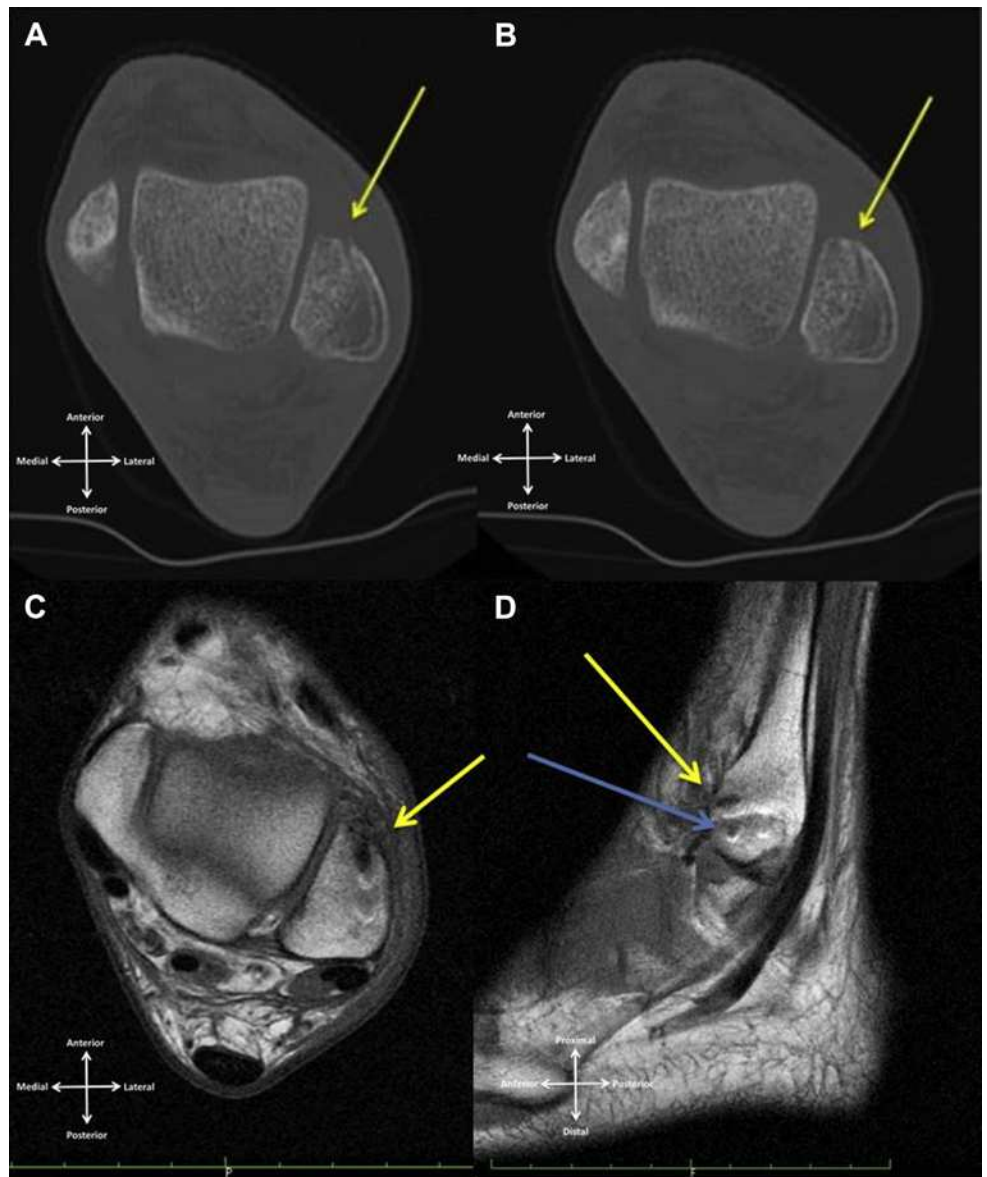


Fig 8. (A, B) Computed tomography evaluation of a left ankle showing the small defects (yellow arrows) caused by the 2.1-mm anchors 2 months postoperatively. (C, D) Magnetic resonance imaging T1 evaluation of left ankle 2 months postoperatively. Some signal changes are explained by the short interval from surgery. (D) On the sagittal view, both tunnels can be identified (blue and yellow arrows).

MaxBraid (polyethylene) suture (Zimmer Biomet) passes through a sleeve of braided polyester suture in a V-shaped configuration, which constitutes the anchoring mechanism to bone. Later, a second loop will also slide and finally lock the soft tissue in place by a similar mechanism.

The second anchor is placed around 5 mm more proximally and will be used to tension the inferior extensor retinaculum (IER). Each anchor has one solid-blue wire and a deployment device with a nitinol loop. Care should be taken to keep each solid-blue wire connected to its corresponding deployment device at all times.

An 18-gauge needle with a No. 3-0 nylon loop is introduced through the aLP and will serve as a suture passer (Fig 6). The needle will trespass the proximal half

of the remnant of the ATFL from inferolateral to superomedial under direct arthroscopic visualization. Firm control of the needle with gentle progression is required to avoid iatrogenic articular damage.

By use of a grasper, the nylon loop is retrieved outside the joint by the aLP and the solid-blue wire from the first anchor is passed through. The nylon loop (including the first solid-blue wire) is subsequently pulled out through the skin. Blunt dissection of subcutaneous soft tissue is performed to avoid superficial peroneal nerve damage and to facilitate the soft-tissue sliding for later pants-over-vest IER reinforcement of the ATFL repair. The solid-blue wire is retrieved through the aLP with the hook probe (Video 1). This wire is connected to its corresponding deployment device by a mosquito clamp (to prevent confusion).

The nylon loop is reinserted (now penetrating more distal on the foot to trespass the IER), and a similar technique is used to retrieve the second solid-blue wire with the hook through the aLP. The foot is brought into a neutral position, and the first anchor is engaged by introducing 3 cm of the solid-blue wire through a nitinol loop on the deployment device. This device has a syringe-like embolus to be pressed, and another Max-Braid loop is detached (blue-white as opposed to the solid-blue wire). This second, blue-white loop is deployed and slides over the solid-blue wire. The surgeon pulls the solid-blue wire in a single continuous movement, making the blue-white loop slide and close, thus tensioning the soft tissue of the ATFL remnant against the footprint (Fig 7). A small pull on the blue-white end of the anchor finally blocks the mechanism.

With the foot being kept in the neutral position, the second anchor is also armed using the previously described technique. At the end of the procedure, ankle stability and full range of motion are confirmed.

The mean tourniquet time in our first 10 consecutive cases was 37 minutes (range, 32 to 47 minutes). A compressive bandage and rigid splint or walker boot in neutral position are used for the first 2 weeks, and non-weight bearing is advised. The stitches are removed around 10 to 14 days.

Two weeks postoperatively, patients are allowed to start periods of active dorsiflexion–plantar flexion and partial weight bearing with a walker boot and crutches. Full weight bearing is achieved around 4 to 6 weeks after surgery.

Discussion

The presented technique enables effective repair of the lateral ankle ligaments in selected cases and if the technical rules are fulfilled (Table 2). However, the possible advantages and limitations of the technique must be considered (Table 3). Patient selection is not always obvious once there is a recognized need for a more objective method to evaluate the quality of the tissue of the ATFL remnant before the operation. The development of more specific instruments is also required to improve this technique in the future.

Recent cadaveric studies have also been considered in the development of arthroscopic ankle instability repair.^{21–27} The described implant can be considered reliable and user-friendly. It also avoids bulky knots,^{4,14} which are another possible source of complaints. The continuous single tensioning reduces complications associated with repeated pendulum movements of classic knot tying and minimizes the risk of glove perforation and skin tears.

Early computed tomography and magnetic resonance imaging evaluation (Fig 8) confirmed that the defect induced in the bone can be considered minimal despite the high pullout resistance of the anchor that we

used.²⁸ It induces minimal bony aggression stating no limitation to any subsequent surgical approach to that area. Being an all-suture anchor, it minimizes the risk of articular damage attributable to implant migration or implant failure.

Future studies are required concerning long-term follow-up. The advance of biomaterials and tissue engineering is fundamental in the development of surgery. However, surgeons must understand the advantages and limitations of every implant to adapt, progress, and improve the outcome.

References

1. de Vries JS, Krips R, Sierevelt IN, Blankevoort L. Interventions for treating chronic ankle instability. *Cochrane Database Syst Rev* 2011;CD004124.
2. van Dijk CN. *Ankle arthroscopy: Techniques developed by the Amsterdam Foot and Ankle School*. Berlin: Springer, 2014.
3. Vega J, Golano P, Pellegrino A, Rabat E, Pena F. All-inside arthroscopic lateral collateral ligament repair for ankle instability with a knotless suture anchor technique. *Foot Ankle Int* 2013;34:1701-1709.
4. Corte-Real NM, Moreira RM. Arthroscopic repair of chronic lateral ankle instability. *Foot Ankle Int* 2009;30:213-217.
5. Takao M, Matsui K, Stone JW, et al. Arthroscopic anterior talofibular ligament repair for lateral instability of the ankle. *Knee Surg Sports Traumatol Arthrosc* in press, available online 16 May, 2015. doi:10.1007/s00167-015-3638-0.
6. Lui TH. Modified arthroscopic Brostrom procedure. *Foot Ankle Surg* 2015;21:216-219.
7. Guillo S, Cordier G, Sonnery-Cottet B, Bauer T. Anatomical reconstruction of the anterior talofibular and calcaneofibular ligaments with an all-arthroscopic surgical technique. *Orthop Traumatol Surg Res* 2014;100:S413-S417.
8. Guillo S, Archbold P, Perera A, Bauer T, Sonnery-Cottet B. Arthroscopic anatomic reconstruction of the lateral ligaments of the ankle with gracilis autograft. *Arthrosc Tech* 2014;3:e593-e598.
9. Matsui K, Takao M, Miyamoto W, Innami K, Matsushita T. Arthroscopic Broström repair with Gould augmentation via an accessory anterolateral port for lateral instability of the ankle. *Arch Orthop Trauma Surg* 2014;134:1461-1467.
10. Cottom JM, Rigby RB. The “all inside” arthroscopic Broström procedure: A prospective study of 40 consecutive patients. *J Foot Ankle Surg* 2013;52:568-574.
11. Acevedo J, Mangone PG. Arthroscopic lateral ankle ligament reconstruction. *Tech Foot Ankle Surg* 2011;10:111-116.
12. Kim ES, Lee KT, Park JS, Lee YK. Arthroscopic anterior talofibular ligament repair for chronic ankle instability with a suture anchor technique. *Orthopedics* 2011;34:273.
13. Nery C, Raduan F, Del Buono A, Asaumi ID, Cohen M, Maffulli N. Arthroscopic-assisted Broström-Gould for chronic ankle instability: A long-term follow-up. *Am J Sports Med* 2011;39:2381-2388.

14. Wang J, Hua Y, Chen S, Li H, Zhang J, Li Y. Arthroscopic repair of lateral ankle ligament complex by suture anchor. *Arthroscopy* 2014;30:766-773.
15. Brown CA, Hurwit D, Behn A, Hunt KJ. Biomechanical comparison of an all-soft suture anchor with a modified Broström-Gould suture repair for lateral ligament reconstruction. *Am J Sports Med* 2014;42:417-422.
16. Suchenski M, McCarthy MB, Chowanec D, et al. Material properties and composition of soft-tissue fixation. *Arthroscopy* 2010;26:821-831.
17. Pereira H, Correlo VM, Silva-Correia J, Oliveira JM, Reis RL, Espregueira-Mendes J. Migration of "bio-absorbable" screws in ACL repair. How much do we know? A systematic review. *Knee Surg Sports Traumatol Arthrosc* 2013;21:986-994.
18. Martinez A, Han Y, Sardar ZM, et al. Risk of glove perforation with arthroscopic knot tying using different surgical gloves and high-tensile strength sutures. *Arthroscopy* 2013;29:1552-1558.
19. Kim SH, Crater RB, Hargens AR. Movement-induced knot migration after anterior stabilization in the shoulder. *Arthroscopy* 2013;29:485-490.
20. van Dijk CN, van Bergen CJ. Advancements in ankle arthroscopy. *J Am Acad Orthop Surg* 2008;16:635-646.
21. Golano P, Vega J, de Leeuw PA, et al. Anatomy of the ankle ligaments: A pictorial essay. *Knee Surg Sports Traumatol Arthrosc* 2010;18:557-569.
22. Giza E, Whitlow SR, Williams BT, et al. Biomechanical analysis of an arthroscopic Broström ankle ligament repair and a suture anchor-augmented repair. *Foot Ankle Int* 2015;36:836-841.
23. Giza E, Shin EC, Wong SE, et al. Arthroscopic suture anchor repair of the lateral ligament ankle complex: A cadaveric study. *Am J Sports Med* 2013;41:2567-2572.
24. Lee KT, Kim ES, Kim YH, Ryu JS, Rhyu IJ, Lee YK. All-inside arthroscopic modified Broström operation for chronic ankle instability: A biomechanical study. *Knee Surg Sports Traumatol Arthrosc* in press, available online 4 July, 2015. doi:10.1007/s00167-014-3159-2.
25. Clanton TO, Campbell KJ, Wilson KJ, et al. Qualitative and quantitative anatomic investigation of the lateral ankle ligaments for surgical reconstruction procedures. *J Bone Joint Surg Am* 2014;96:e98.
26. Drakos M, Behrens SB, Mulcahey MK, Paller D, Hoffman E, DiGiovanni CW. Proximity of arthroscopic ankle stabilization procedures to surrounding structures: An anatomic study. *Arthroscopy* 2013;29:1089-1094.
27. Neuschwander TB, Indresano AA, Hughes TH, Smith BW. Footprint of the lateral ligament complex of the ankle. *Foot Ankle Int* 2013;34:582-586.
28. Barber FA, Herbert MA, Hapa O, et al. Biomechanical analysis of pullout strengths of rotator cuff and glenoid anchors: 2011 update. *Arthroscopy* 2011;27:895-905.